

A Systematic Approach to Restoring Full Arch Length with Maxillary Fixed Implant Reconstruction: The PATZi Protocol

Shouvik Ponnusamy, DMD¹/Juan Gonzalez, DMD²/Dan Holtzclaw, DDS, MS³

The traditional configuration of four maxillary implants to restore full-arch maxillary fixed implant prostheses is not without pitfalls. Intraoperative variability, such as bone quality and quantity, may lead to unexpected intraoperative challenges that may not allow for execution of the original treatment plan. Additionally, extensive maxillary sinus pneumatization may inhibit posterior spread and lead to a shortened dental arch or excessive cantilever forces. The PATZi protocol is a systematized algorithm for maxillary full-arch implant treatment planning that addresses such intraoperative surprises and achieves full arch length in the planned prosthesis. PATZi also assigns a numbering classification to each implant configuration, which leads to uniform communication and grading of surgical difficulty, as well as predictable planning for developing future salvage plans. By using the PATZi protocol as a guideline, the surgeon may improve composite torque value and anteroposterior (AP) spread, eliminate distal cantilever forces, and ultimately improve the predictability of the prosthetic treatment plan. *Int J Oral Maxillofac Implants* 2023;38:996–1004. doi: 10.11607/jomi.10153

Keywords: full-arch implants, all-on-x, fixed hybrid prosthesis, implant protocol

Full-arch fixed implant rehabilitation treatments seem to be performed more often in the present day than ever before. In the United States, life expectancy continues to increase, and the edentulous patient population is expected to continually grow in the future.¹ This growth may contribute to the increased demand and expectation for same-day fixed dental prostheses. Traditional bone graft reconstruction with delayed implant placement is associated with significant increases in morbidity, total treatment time, and treatment cost when compared to graftless approaches.² Achieving a graftless, immediately loaded configuration of stable implants is not without challenge and often involves intraoperative impromptu decision-making. Several requirements must be met to avoid common pitfalls, such as delivery of a shortened prosthetic dental arch, inadequate composite torque value for immediate prosthetic loading, or additional surgical procedures. The authors propose the PATZi protocol for use as a preoperative and intraoperative workflow algorithm that serves as a framework for full-arch maxillary implant surgery and prosthetic rehabilitation. This article serves to present

the novel PATZi protocol algorithm, as well as five cases demonstrating its application.

GENERAL PROTOCOL APPROACH

The PATZi protocol is a systematic algorithm focused on employing particular dental implant techniques in distinct regions of maxillary anatomy in a specific, logical sequence (Fig 1). The primary goal is to allow for immediate loading of a provisional fixed prosthesis of satisfactory arch length while prioritizing less invasive surgical techniques over more invasive approaches. The workflow uniquely addresses a commonplace occurrence among implant surgeons, who may encounter a lack of sufficient insertion torque (< 35 Ncm)³ or an inability to obtain primary stability in a particular planned implant treatment. The protocol also employs relevant backup options for the future, preserving strategic bone stock for additional implants should future implant failures require additional implant placement to maintain the patient in a fixed prosthesis.

When following the PATZi protocol, if the first implant placement attempt in the sequence results in an inability to obtain primary stability or sufficient insertion torque, that implant attempt would be aborted, and the next technique outlined in the algorithm would then be performed in a stepwise fashion. The process is then continued until a satisfactory configuration of implants is obtained. In the rare case that the entire algorithm is exhausted, and appropriate primary stability, composite torque value, and anteroposterior

¹Niva Dental Specialists, Toothsome Inc, Austin, TX, USA.

²Private Practice, Austin, TX, USA.

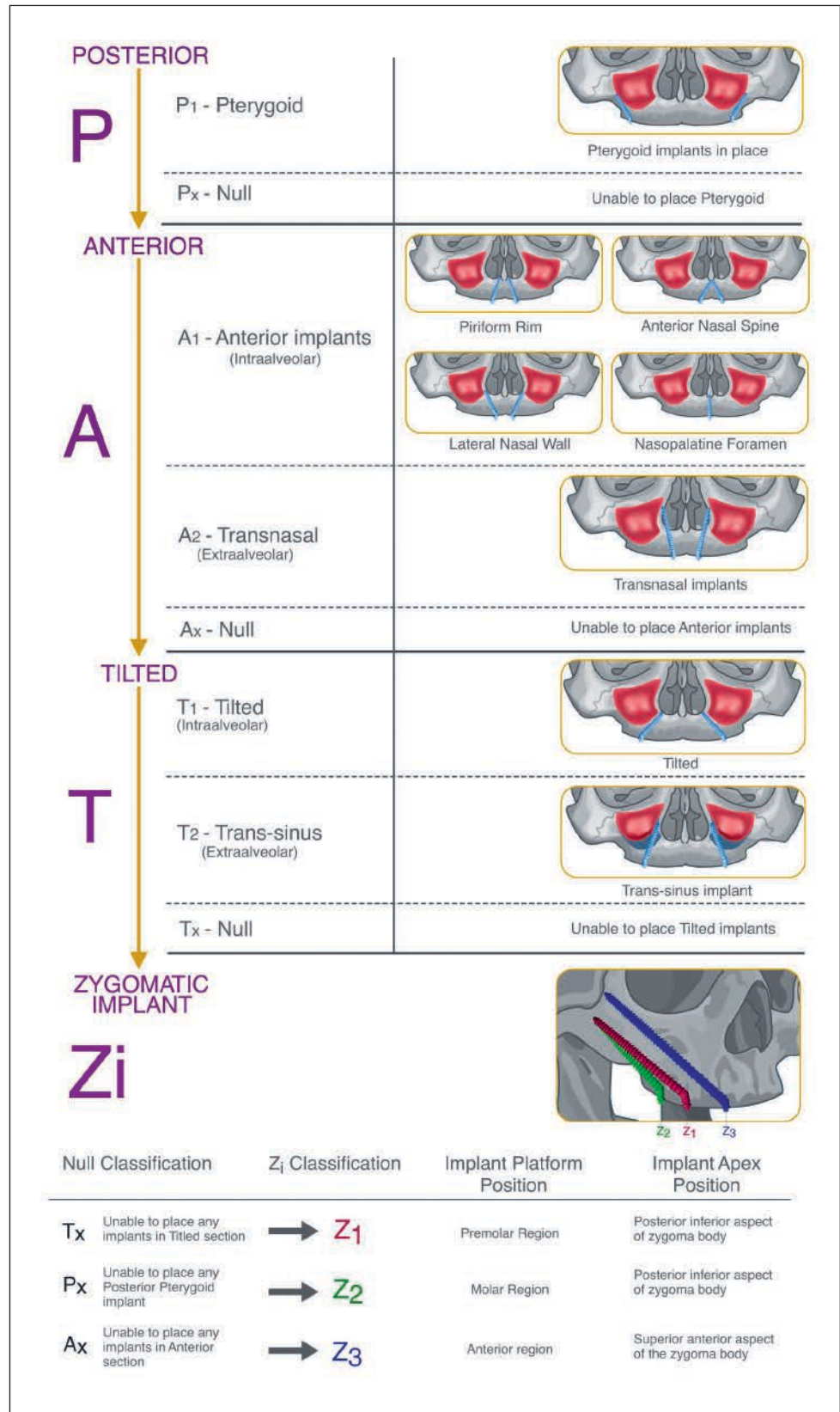
³Fixed Arch Services, Affordable Care LLC.

Correspondence to: Shouvik Ponnusamy, 1511 Rimstone Drive, Cedar Park, TX 78613, USA.
Email: drsamyo.oms@gmail.com

Submitted July 6, 2022; accepted November 2, 2022.

©2023 by Quintessence Publishing Co Inc.

Fig 1 Visualization of the PATZi workflow algorithm. The first three categories are separated by region, and each region is further separated into intra-alveolar, extra-alveolar, and null classifications. If the first implant is not able to be placed, the next implant classification is attempted, and the workflow is continued down the algorithm. If all attempts within a category are unsuccessful, that section is classified as null, and the specified respective zygomatic implant will be placed to attain anchorage in that region in the Zi stage of the algorithm.



(AP) spread are not achieved, then only in this scenario would alternative options need to be considered, such as a removable denture, bone grafting reconstruction for delayed implant placement, or use of a subperiosteal patient-specific implant.

In addition to providing an intraoperative surgical algorithm to aid preoperative treatment planning, PATZi also acts as a classification system. This numbering system helps classify the severity of the maxillary resorption and/or defect and the degree of difficulty of the involved surgical techniques, as well as guide the surgeon to formulate salvage backup plans in case of potential future implant failures. The numbering system also streamlines communication between surgeons and restoring providers when discussing cases. It is beyond the scope of this article to provide an in-depth explanation and analysis of each individual technique described, as the focus of this paper is the solution-based decision-making nature of the PATZi protocol.

PATZi PROTOCOL

Posterior

The “P” in the PATZi protocol stands for Posterior. This refers to implants to be placed in the molar region of the maxilla (Bedrossian classification III).⁴ Given that the vast majority of full-arch implant surgery cases have a degree of maxillary atrophy, traditional axial implants are rarely considered here due to the lack of vertical and horizontal bone stock and the D4 type bone composition found in this region. The first implants to be placed in the protocol are pterygoid implants (P_1), as depicted in Fig 1. Pterygoid implants are endosseous implants placed posteromedially to engage the cortical bone of the pterygomaxillary complex. Such implants are well documented in the literature to provide satisfactory success rates and have been proven to significantly improve AP spread.^{5,6} If pterygoid implants are unable to be placed, the posterior section is classified as null (P_x), and steps to address alternative posterior support are to be addressed later in the protocol. The algorithm is then continued to the next section.

Anterior

The “A” in the PATZi protocol stands for Anterior. After completion of the Posterior section, attention is directed to the anterior maxilla (Bedrossian classification I).³ Anterior maxillary (A_1) implant placement is attempted. Various configurations may be used within the A_1 category to help engage the apex of the implant into cortical bone, such as the piriform rim, anterior nasal spine, lateral nasal wall, and nasopalatine canal. If A_1 implants are satisfactorily placed, the Anterior section is complete, and the algorithm is continued to the next

section. However, should A_1 implants not be achieved, the algorithm progresses to the placement of transnasal implants (A_2), as described by Camargo et al.⁷ Transnasal implants engage the body and apex of the implant into the thick cortical bone along the lateral nasal wall and into the frontal process of the maxilla. Should transnasal implants not be attained, the anterior section is deemed null (A_x), and alternative anterior anchorage will be addressed further down the algorithm. The workflow is then continued to the next section.

Tilted

The “T” in the PATZi protocol stands for Tilted, which refers to the premolar region of the maxilla (Bedrossian classification II).⁴ Traditional tilted implants are placed anterior to the maxillary sinus wall (T_1). If T_1 implants can be placed, the Tilted section is complete, and the surgeon then continues onto the next section in the protocol. Should this not be attainable, transsinus (T_2) implant placement is then attempted. As described by Jensen et al,⁸ transsinus implants traverse through the maxillary sinus anteriorly, engaging the apex of the implant into the lateral nasal wall. Should transsinus implants also not be attainable, the Tilted section is classified as null (T_x), and an alternative method for a fixture in the premolar region will be employed in the next section of the workflow.

Zygomatic Implants

The final section in the PATZi protocol is “Zi” for Zygomatic implants. The first three letters of PATZi refer to specific anatomic areas, whereas Zi refers to the specific type of implant, which can address multiple regions across the maxillary arch. The zygomatic implant placement method is dictated by the previous three sections of the algorithm and will serve to compensate for any of the sections that were unable to have implants successfully placed. If posterior, anterior, and tilted implant placement attempts were all successful, and no null classifications were assigned, then the algorithm is complete and no zygomatic implants are indicated.

However, in the case where any null classification in the “P,” “A,” or “T” sections is encountered, zygomatic implant placement is indicated. The orientation and location of the zygomatic implant may be placed to act as anchorage for the premolar (Z_1), molar (Z_2), or anterior (Z_3) regions of the maxillary arch. The platforms and apices, which are technique sensitive and of the utmost importance, are specified in Fig 1. This particularity in placement of zygomatic implants is necessary to preserve the remaining zygoma body for future zygomatic implants in case an implant failure occurs and requires replacement in the future.

Thus, the Zi section of the protocol is as follows: If a T_x was encountered in the Tilted section, then a zygomatic

Combination Null Classifications	Zi Placement Trajectory	Additional Considerations
P_x, T_x	Z_2	<ul style="list-style-type: none"> - Recommend additional anterior anchorage if possible - Consider nasopalatine foramen implant
A_x, T_x	Z_1, Z_3	<ul style="list-style-type: none"> - Quad zygomatic implants with pterygoid implant support - See Case 5 as example
P_x, A_x	Z_2, Z_3	<ul style="list-style-type: none"> - Traditional quad zygomatic implant configuration - Consider nasopalatine foramen implant for additional anchorage
P_x, A_x, T_x	Z_2, Z_3	<ul style="list-style-type: none"> - Traditional quad zygomatic implant configuration - Consider nasopalatine foramen implant for additional anchorage

Fig 2 In cases where severe atrophy exists, null classifications may occur in multiple categories, not just one. In the case of combined null classifications, particular consideration of zygomatic implant placement is important to maximize AP spread while utilizing what little bone stock is available.

implant is placed with its platform emerging in the pre-molar area and its apex at the postero-inferior portion of the zygoma (Z_1). If a P_x was encountered in the Posterior section, then a zygomatic implant is placed with the platform emerging in the molar area and its apex at the postero-inferior portion of the zygoma (Z_2). If an A_x was encountered in the Anterior section, then a zygomatic implant is placed with its platform emerging in the anterior region and its apex at the anterior superior aspect of the zygoma (Z_3) (Fig 1). A situation with a combination of T_x, P_x , and A_x would only be encountered in severe atrophy cases, and only then would both Z_2 and Z_3 implants or quad zygomatic implants be considered (Fig 2). In this configuration, the authors suggest using an additional nasopalatine foramen implant for increased anchorage and composite torque value,⁹ if possible. Alternatives to immediately loaded fixed prostheses—such as bone graft reconstruction and delayed implant placement, subperiosteal patient-specific implants, or a definitive removable prosthesis—should only be considered if the Zi section of the protocol is not able to deliver satisfactory stability.

THE PATZI PROTOCOL APPLIED: A CASE SERIES OF FIVE MAXILLARY ARCHES

Case 1: $P_1A_1T_1Z_0$

Case 1 showed a maxillary arch where zygomatic implants were not indicated, which is a configuration

commonly known as the PFAST technique, as described by Holtzclaw and Telles (Fig 3).⁶ Following the PATZi protocol, the workflow was implemented as follows: First, pterygoid implants were placed bilaterally (P_1). Attention was then directed to the anterior region, where bilateral intra-alveolar implants that engaged the piriform rim cortical bone were achieved (A_1). Then, traditional tilted implants (T_1) were placed in the pre-molar region. Given the primary stability and satisfactory AP spread, the PATZi protocol demonstrated no indication for zygomatic implants (Z_0).

Case 2: $P_1A_1T_xZ_1$

Case 2 showed a full-arch configuration where traditional tilted implants were not able to be placed due to insufficient bone stock (Fig 4). Following the PATZi protocol, bilateral pterygoid implants were placed first (P_1), followed by anterior intra-alveolar implants that engaged the piriform rim (A_1). Continuing to the tilted section of the PATZi protocol, tilted implants were attempted without success. The (T_x) classification was assigned, and the algorithm was followed into the Zi category, where Z_1 configuration zygomatic implants were placed satisfactorily. Of note, the apex of the zygomatic implant was strategically kept to the inferior and lateral aspect of the zygoma body, intentionally leaving sufficient anterosuperior bone for a potential additional zygomatic implant should an anterior or zygomatic implant fail in the future.

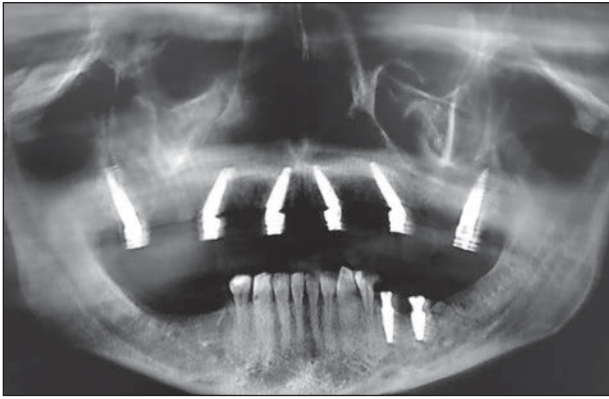


Fig 3 Case 1: $P_1A_1T_1Z_0$. By following the PATZi algorithm, each section was successfully fulfilled with intra-alveolar implants. No zygomatic implants were indicated.

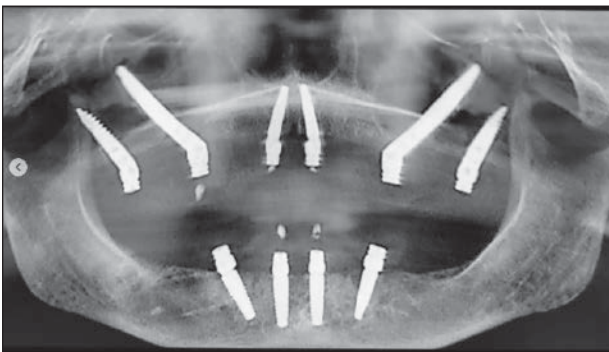


Fig 4 Case 2: $P_1A_2T_xZ_1$. Use of the PATZi algorithm in the case of null classification in the Tilted section (T_x). Thus, the indication to place a Z_1 -oriented zygomatic implant was met. In the authors' experience, the zygomatic implant that is most often required is in the premolar area, which occurs due to extensive sinus pneumatization and/or the inability to attain a tilted intra-alveolar (T_1) implant in the premolar region.

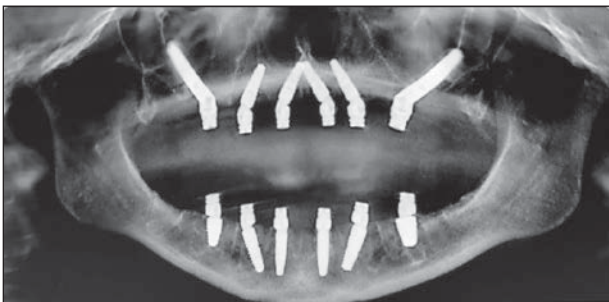

Fig 5 Case 3: $P_xA_1T_1Z_2$. Case 3 demonstrates a situation where pterygoid implant placement attempts were unsuccessful. Following the PATZi algorithm, Z_2 -oriented zygomatic implants were placed, allowing satisfactory AP spread with first molar occlusion, despite the lack of pterygoid implants in place.

Case 3: $P_xA_1T_1Z_2$

Case 3 demonstrates a situation where traditional posterior implants were not able to be placed (Fig 5). Pterygoid implants were attempted and subsequently proven to be unsuccessful due to lack of primary

stability. Therefore, the (P_x) classification was assigned. Both traditional anterior (A_1) and tilted implants (T_1) were achieved. At this point, if the surgeon stopped with only four implants, the limitation of AP spread would have likely resulted in a significantly shortened dental prosthetic arch or a significant distal prosthetic cantilever.^{10,11} The PATZi algorithm was then followed to successfully place Z_2 -oriented implants, leading to a satisfactory composite torque value and AP spread. The apices of the zygomatic implants were kept in the posteroinferior aspect of the zygomatic body, with the platform of the implant positioned within the molar area. This position allows for the potential placement of an anterior zygomatic implant as a salvage option, should the patient experience an implant failure in the future.

Case 4: $P_1A_2T_xZ_1$

Case 4 demonstrates how when traditional A_1 implants cannot be placed, an alternative to anterior maxillary intra-alveolar implants must be considered (Fig 6). Utilizing the PATZi protocol, bilateral pterygoid implants were successfully placed (P_1). To avoid the morbidity associated with an anteriorly based zygomatic implant, such as in the case of quad zygoma implants, extra-long transnasal implants may be placed in this region.¹² Transnasal (A_2) implants were placed, given the appropriate indications.⁷ Tilted implants were unable to be placed (T_x), which then led to the bilateral placement of Z_1 -oriented zygomatic implants. Case 4 demonstrates the vast applicability of the PATZi protocol to the varying degrees of patient anatomical and intraoperative variability.

Case 5: $P_1A_xT_xZ_{1,3}$

Case 5 showed severe insufficiency of anterior maxillary bone for traditional implants, though the indications for a transnasal implant were not met (Fig 7). The PATZi sequence began with bilateral pterygoid implant placement (P_1), at which point it was appreciated that anterior and tilted intra-alveolar implant placements were not possible (A_x , T_x). Following the PATZi protocol, given that multiple sections were deemed null, both Z_1 , and Z_3 zygomatic implants were placed (see Fig 2). Despite the severe atrophy of bone, this configuration allowed for high composite torque value, satisfactory AP spread, full arch length prosthetics, and same-day immediate loading.

FULL ARCH LENGTH OUTCOMES

In addition to traditional implant and fixed hybrid denture prosthesis success outcomes, the authors would like to introduce an additional outcome measure that

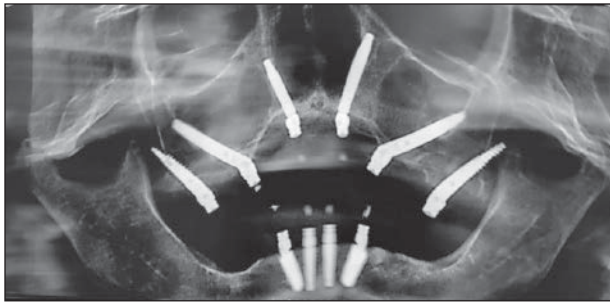


Fig 6 Case 4: P₁A₂T_xZ₁. Case 4 demonstrates the use of anterior extra-alveolar implants (transnasal implants). Following the PATZI protocol, an anterior zygomatic implant was avoided due to the bilateral transnasal implant placement. This case demonstrates the PATZI workflow's prioritization of less invasive techniques.

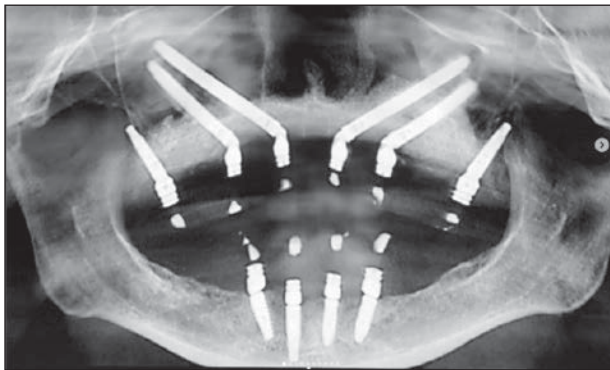


Fig 7 Case 5: P₁A_xT_xZ_{1,3}. Case 5 demonstrates complete extra-alveolar anchorage. The PATZI algorithm sequence was followed successfully, and a combination null classification was encountered. Thus, dual zygomatic implants were required to attain anchorage in both the anterior and premolar section. Due to successful pterygoid implant placement, full arch length without a prosthetic cantilever was attained.

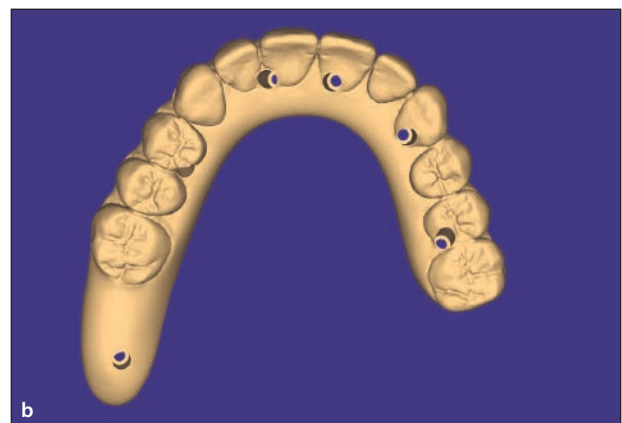
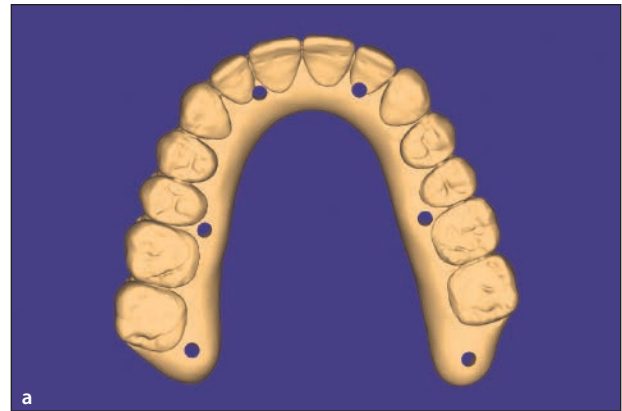


Fig 8 The Full Arch Ratio (FAR) is calculated by grouping maxillary fixed hybrid denture prosthetic designs into two categories.

$$FAR = 1 - \left[\frac{\text{cantilevered arch}}{\text{zero cantilevered arch}} \right] \times 100.$$

Figure 8a represents the denominator of FAR. These are the prosthetic designs that incorporate < 12 teeth, or a design with 12 teeth that incorporate a ≥ 1 tooth unsupported distal cantilever, as seen with tooth 14 (universal numbering system). Figure 8b represents the numerator of the FAR, which are prosthetic designs which incorporate ≥ 12 teeth with no unsupported distal cantilever.

specifically addresses arch length and cantilever reduction in maxillary full-arch rehabilitations. The authors propose the novel Full-Arch Ratio (FAR) as a measure to specifically quantify aggregate maxillary full-arch fixed hybrid denture prosthetic arch length and cantilever outcomes.

The FAR is calculated by determining the number of maxillary arches restored with either the presence of a distal cantilever of ≥ 1 tooth or a prosthetic design of < 12 teeth. This is divided by the number of maxillary arches without any distal cantilever or a prosthetic design ≥ 12 teeth. Disregard any cases of division by zero. The resulting value is subtracted from 1, and that result is then multiplied by 100, resulting in a range from negative infinity to 100, with a goal of reaching as close to 100 as possible. Therefore, the equation is written as follows: $FAR = 1 - \left[\frac{\text{cantilevered arch}}{\text{zero cantilevered arch}} \right] \times 100$. The measure can be taken at any various time intervals that a clinician may

wish to evaluate. The authors' restorative protocol calls for a 12- to 14-tooth prosthetic design with the PATZI protocol when possible (Fig 8a). This is compared to the non-PATZI, traditional All-on-4 implant configuration, which typically only uses a 10-tooth prosthetic design that is often only achievable with the incorporation of a ≥ 1 tooth cantilevered distal extension. With the authors' implementation of the PATZI protocol, 142 maxillary full-arch rehabilitations were completed in a 1-year timeframe. All 142 full-arch rehabilitations were immediately loaded, and of those, only 9 had final restorations designed to incorporate a distal cantilever and/or a design of ≤ 12 teeth (Fig 8b). These results illustrate a FAR of 94 and a 100% immediate load rate, demonstrating how the use of the PATZI protocol may significantly contribute to prosthetic distal cantilever elimination and the realization of satisfactory prosthetic arch length outcomes.

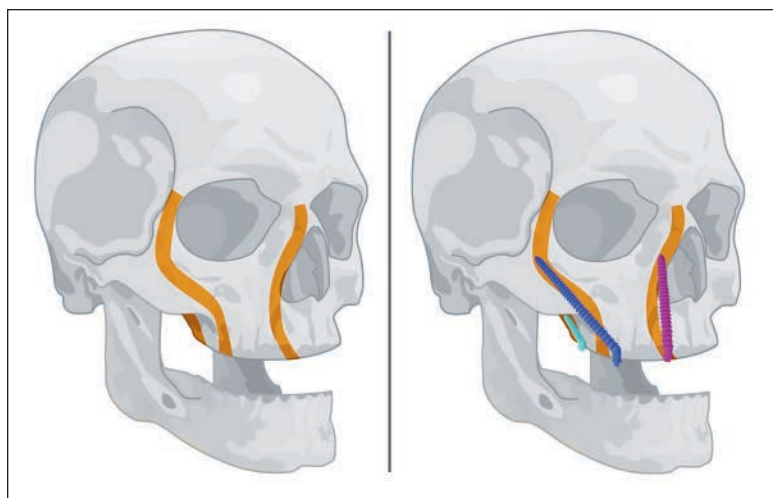


Fig 9 The anatomical vertical craniofacial buttresses mirror the extra-alveolar implant placement positions. This principle allows select extra-alveolar anchorage to be utilized when intra-alveolar implant anchorage is not possible.

DISCUSSION

Introduced by Maló et al,¹³ the traditional All-on-4 implant configuration has been widely adopted and used to restore a full-arch fixed hybrid denture prosthesis. However, it is not without its pitfalls. Due to the significant pneumatization of the maxillary sinuses, the posterior implants may be placed with access holes that only allow emergence to the first premolars. This may lead to inadequate AP spread, unfavorable distal prosthetic cantilevers, a shortened dental arch prosthesis, and poor patient quality of life.^{11,14,15} Additionally, should one of the four implants fail, additional complications may occur if the prosthesis remains functionally loaded on only three implants.¹⁶ When considering the biomechanical perspective, cantilever elimination significantly impacts prosthetic design and long-term reduction of surgical and prosthetic complications. Improving the FAR ratio as a direct result of placing sufficient implants in accordance with the PATZi protocol may not only improve the composite torque value, but also improve AP spread, eliminate cantilever forces, and ultimately reduce long-term complications.^{5,16,17}

The anchorage of implants into cortical bone is also a key consideration within the PATZi protocol. Given the variability of maxillary sinus pneumatization, thin ridge width, and overall lack of alveolar bone stock, extra-alveolar implants may be required in full-arch implant rehabilitation, such as the use of zygomatic implants. Pterygoid and transnasal implants are also examples of extra-alveolar implants that engage cortical bone beyond the alveolus. Transnasal, zygomatic, and pterygoid implants are anchored within the vertical buttresses of the craniofacial skeleton.^{7,18,19} These implants engage the cortical bone of the lateral nasal walls, zygomatico-maxillary buttresses, and pterygomaxillary buttresses, respectively, following the same principles as LeFort I

downfracture and fixation.²⁰ The authors believe in applying classic craniofacial buttress principles to provide sufficient stability with extra-alveolar dental implants when indicated (Fig 9).

Extensive preoperative planning is also pivotal to success with full-arch implant rehabilitation. Although extra-alveolar implants may involve the use of advanced techniques and should only be placed by appropriately trained and experienced surgeons, successful surgical placement alone is not enough to lead to a satisfactory prosthetic outcome. It is essential that the implant platforms of such extra-alveolar implants are tailored to the planned prosthesis in accordance with the appropriate prosthodontic principles.⁴ Ponnusamy and Miloro²⁰ described a prosthetically driven routine with respect to treatment planning zygomatic implant placement. This restoratively driven, or “crown down,” approach is crucial to full-arch implant rehabilitation and is imperative when using extra-alveolar implants for anchorage.

However, no matter how much meticulous treatment planning is performed in the preoperative period, patient anatomical variability exists. Insufficient primary stability or insertion torque may be encountered intraoperatively, which necessitates an intraoperative treatment plan change. The authors note such potential occurrences with fully guided full-arch implant placement systems. Should the clinical situation necessitate intraoperative changes, the surgeon must be able to adapt midprocedure and change course. This is where the PATZi protocol provides a systematic and consistent structure that may help a clinician achieve a satisfactory biomechanical implant configuration without the concern of a shortened dental arch prosthesis, insufficient torque value, or significant prosthetic cantilevers. Additionally, the nature of the classification system within the PATZi protocol not only provides a clear course of decision-making, but it also allows the surgeon to grade

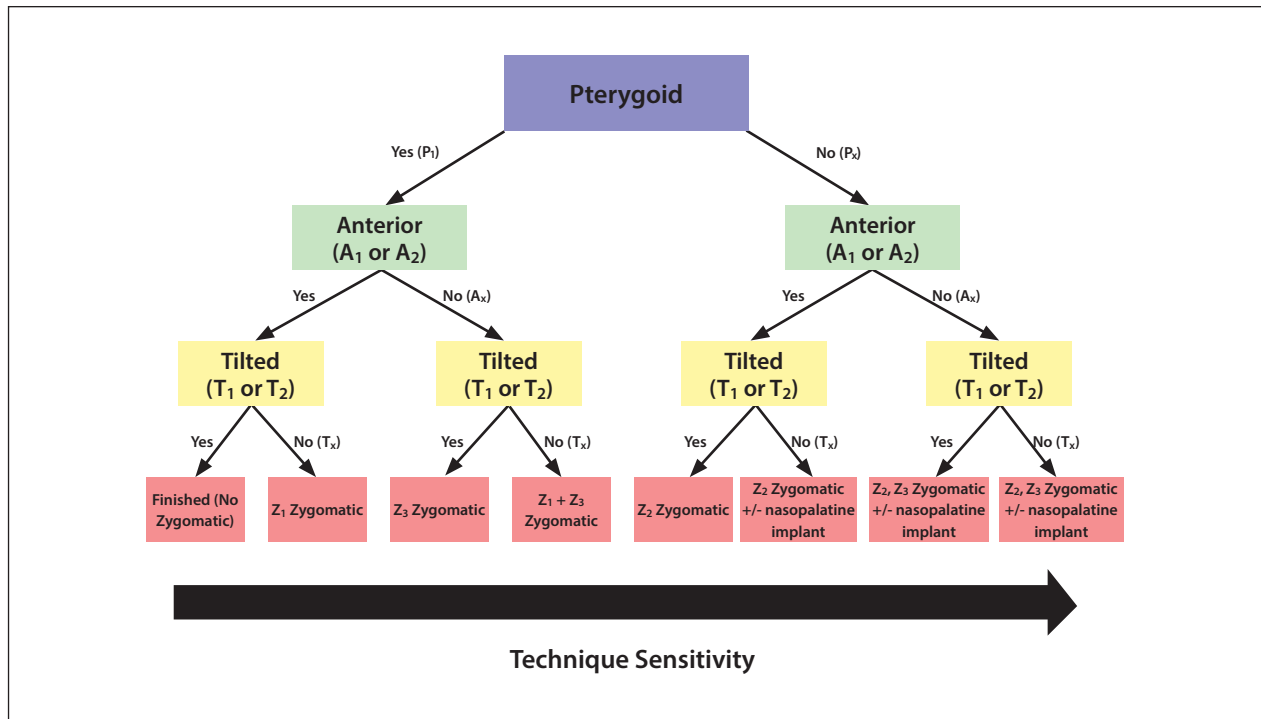


Fig 10 The PATZi workflow as a comprehensive decision tree, mapping out the various combinations of implant configurations. It should be noted that surgical difficulty and technique sensitivity increases as more severe atrophy and combination of null classifications occurs.

or stage the particular implant configuration used for each individual case (Fig 10). This helps the surgeon quickly identify degree of surgical complexity, allows for comprehensive and uniform communication with restorative colleagues, and provides future contingency planning for implant salvage should failures occur.

CONCLUSION

Full-arch implant reconstruction applies a distinct and invariable result—a fixed full-arch prosthetic—to a set of vast and inconsistent variabilities, such as patient anatomy, parafunctional habits, and the condition of the existing dentition. Given the extent of preoperative and intraoperative variability that exists among the patient population, the PATZi protocol may serve as a guide to help surgeons deliver the desired result successfully and consistently, as well as appropriately classify and plan for future indicated interventions.

ACKNOWLEDGMENTS

The authors declare no conflicts of interest.

REFERENCES

1. Turkyilmaz I, Company AM, McGlumphy EA. Should edentulous patients be constrained to removable complete dentures? The use of dental implants to improve the quality of life for edentulous patients. *Gerodontology* 2010;27:3–10.
2. Aparicio C, Manresa C, Francisco K, et al. Zygomatic implants: Indications, techniques and outcomes, and the zygomatic success code. *Periodontol* 2000 2014;66:41–58.
3. Ogawa T, Dhaliwal S, Naert I, et al. Impact of implant number, distribution and prosthesis material on loading on implants supporting fixed prostheses. *J Oral Rehabilitation* 2010;37: 525–531.
4. Bedrossian E, Sullivan RM, Fortin Y, Malo P, Indresano T. Fixed-prosthetic implant restoration of the edentulous maxilla: A systematic pretreatment evaluation method. *J Oral Maxillofac Surg* 2008;66: 112–122.
5. Ren J, Shu L. Pterygoid implant-based “VIV” design for rehabilitation of extreme maxillary atrophy. *J Craniofac Surg* 2022;33:2195—2198.
6. Holtzclaw D, Telles R. Pterygoid fixated arch stabilization technique (PFAST): A retrospective study of pterygoid dental implants used for immediately loaded full arch prosthetics. *J Implant Adv Clin Dent* 2018;10:6–17.
7. Camargo VB, Baptista D, Manfro R. Implante transnasal (Técnica Vanderlim) como opção ao segundo implante zigomático. In: Coppêdê A (ed). *Soluções clínicas para reabilitações totais sobre implantes sem enxertos ósseos*. Santos Publications, 2019:198–214.
8. Jensen OT, Cottam J, Ringeman J, Adams M. Trans-sinus dental implants, bone morphogenetic protein 2, and immediate function for all-on-4 treatment of severe maxillary atrophy. *J Oral Maxillofac Surg* 2012;70:141–148.
9. Peñarrocha David, Candel E, Guirado JLC, Canullo L, Peñarrocha M. Implants placed in the nasopalatine canal to rehabilitate severely atrophic maxillae: A retrospective study with long follow-up. *J Oral Implantol* 2014;40: 699–706.

10. Fueki K, Igarashi Y, Maeda Y, et al. Effect of prosthetic restoration on oral health-related quality of life in patients with shortened dental arches: A multicentre study. *J Oral Rehabil* 2015;42:701–708.
11. Tolstunov L, Thai D, Arellano L. Implant-guided volumetric analysis of edentulous maxillary bone with cone-beam computerized tomography scan. Maxillary sinus pneumatization classification. *J Oral Implantol* 2012;38:377–390.
12. Almeida PHT, Cacciaccane SH, Arcasas Junior A. Extra-long transnasal implants as alternative for quad zygoma: Case report. *Ann Med Surg (Lond)* 2021;68:102635.
13. Maló P, Rangert B, Nobre M. All-on-4 immediate-function concept with Brånemark SystemR implants for completely edentulous maxillae: A 1-year retrospective clinical study. *Clin Implant Dent Relat Res* 2005;7(suppl 1):S88—S94.
14. Fueki K, Igarashi Y, Maeda Y, et al. Effect of prosthetic restoration on masticatory function in patients with shortened dental arches: A multicentre study. *J Oral Rehabil* 2016;43:534–542.
15. Walter L, Greenstein G. Utility of measuring anterior-posterior spread to determine distal cantilever length off a fixed implant-supported full-arch prosthesis. *J Am Dent Assoc* 2020;151:790–795.
16. Tribst JPM, Dal Piva AMO, Borges ALS, Rodrigues VA, Bottino MA, Kleverlaan CJ. Does the prosthesis weight matter? 3D finite element analysis of a fixed implant-supported prosthesis at different weights and implant numbers. *J Adv Prosthodont* 2020;1:67–74.
17. Aparicio C, Polido WD, Zarrinkelk HM. The zygoma anatomy-guided approach for placement of zygomatic implants. *Atlas Oral Maxillofac Surg Clin North Am* 2021;29: 203–231.
18. Graves SL. The pterygoid plate implant: A solution for restoring the posterior maxilla. *Int J Periodontics Restorative Dent* 1994;14:512–523.
19. Markowitz BL, Manson PN. Panfacial fractures: Organization of treatment. *Clin Plast Surg* 1989;16:105–114.
20. Ponnusamy S, Miloro M. A novel prosthetically driven workflow using zygomatic implants: The restoratively aimed zygomatic implant routine. *J Oral Maxillofac Surg* 2020;78:1518–1528.